BMC Oral Health

RESEARCH

Open Access

Postoperative nostril asymmetry after Le Fort I osteotomy: an analysis of the interplay between alar cinch sutures and intubation side

Emrah Soylu[1,2], Selin Çelebi[3], Begüm Yener[1], Taner Öztürk[4*], Gökhan Çoban[4], Dilek Günay Canpolat[1], Seher Orbay Yaşlı[1] and Ahmet Emin Demirbaş[1]

Abstract

Background Orthognathic surgery aims to improve jaw function and facial aesthetics through bilateral sagittal split osteotomy and Le Fort I osteotomy. Recent treatment goals emphasize careful evaluation of aesthetic outcomes, particularly in the nasolabial area, as repositioning the upper jaw can lead to significant soft tissue changes. This study investigates whether nasotracheal intubation affects nostril symmetry in patients undergoing Le Fort I osteotomy with/without cinch sutures.

Methods A retrospective analysis of adult patients (ages 18–30, ASA I-II) who underwent Le Fort I surgery with nasotracheal intubation at Erciyes University from 2012 to 2020 was conducted. Preoperative and at six months postoperative, 3D images were analyzed to measure nostril width (NW). Patients were categorized into Group I (with cinch sutures) and Group II (without cinch sutures). Soft tissue changes were assessed using the 3dMD imaging system.

Results Eighty-five patients were included. Significant changes in nostril width were observed between preoperative and six-month postoperative assessments in both groups. Right intubation led to increased right nostril diameter in both groups, while the left nostril showed significant change only in the cinch group. For left intubation, no significant changes were observed in nostril dimensions in the cinched group. The findings indicate that intubation side significantly influences nostril symmetry, particularly in cases of right nasotracheal intubation. The use of cinch sutures does not fully mitigate the widening effect, suggesting that the timing of cinch suture placement may be crucial.

Conclusion This study demonstrates that the nasotracheal intubation side may influence postoperative nostril width following Le Fort I osteotomy, particularly in patients receiving alar cinch sutures. The findings suggest that the physical presence of a nasotracheal tube during wound closure could interfere with the accurate assessment of alar base width.

*Correspondence:
Taner Öztürk
tanertr35@gmail.com

Full list of author information is available at the end of the article

© The Author(s) 2026. **Open Access** This article is licensed under a Creative Commons Attribution-NonCommercial-NoDerivatives 4.0 International License, which permits any non-commercial use, sharing, distribution and reproduction in any medium or format, as long as you give appropriate credit to the original author(s) and the source, provide a link to the Creative Commons licence, and indicate if you modified the licensed material. You do not have permission under this licence to share adapted material derived from this article or parts of it. The images or other third party material in this article are included in the article's Creative Commons licence, unless indicated otherwise in a credit line to the material. If material is not included in the article's Creative Commons licence and your intended use is not permitted by statutory regulation or exceeds the permitted use, you will need to obtain permission directly from the copyright holder. To view a copy of this licence, visit http://creativecommons.org/licenses/by-nc-nd/4.0/.

Keywords Alar cinch suture, Le fort i osteotomy, nasotracheal intubation

Introduction

Orthognathic surgery aims to enhance jaw function and facial aesthetics through bilateral sagittal split osteotomy and Le Fort I osteotomy [1]. The treatment goals of orthognathic surgery have changed recently. Esthetic outcomes are evaluated carefully to predict the undesirable soft tissue changes in the nasolabial area. Repositioning the upper jaw significantly influences the appearance of the nasolabial region, commonly resulting in modifications such as nasal tip alteration, upward nasal rotation, increased nasal width, enhanced columella, and upper lip projection [2]. Widening of the alar base frequently occurs following maxillary osteotomies, particularly in cases involving impaction or advancement [3]. The surgical outcome is not only influenced by skeletal adjustments but also by the extent of subperiosteal dissection. Releasing the facial muscles around the anterior nasal spine allows them to retract laterally and leads to asymmetrical elevation of the nasal base. Several strategies have been proposed to prevent these undesirable effects. Soft tissue closure techniques such as V-Y suture and alar cinch suture are frequently used to improve the aesthetics of the nasolabial region [4]. The alar base cinch suture, proposed by Millard to manage nasal base tissues in cleft lip patients, is commonly used to address these concerns [5]. According to Collins and Epker [6], these sutures stabilize alar width and support nasal tissues, optimizing aesthetic outcomes. Among these, there were several proposals for modifications of the alar cinch technique, and different studies to show the effectiveness of one type among all others. Rauso et al. described a classification of alar cinch suture that includes four types, covering all cinching techniques. Although all the techniques are described, the results are controversial [7].

Due to the nature of orthognathic surgery, nasotracheal intubation is the preferred method to put patients under general anesthesia [8], in which the intubation tube passes through one of the nostrils and is secured to the nasal septum by placing a basic suture with/without a sterile wound drape. The nasal Ring, Adair, and Elwyn (RAE) and North Polar nasotracheal tube is commonly used in oral and maxillofacial surgery owing to its preformed design, which facilitates surgical access and tube stability [9]. The surgeon's focus during the surgery is directed to the intra-oral region; hence, the security of the airway and the retraction of the nasal tissues can be postponed.

To our knowledge, no study has specifically investigated nostril width following cinch suture placement in the presence of a nasotracheal intubation tube. Therefore, this study aims to assess whether intubation side effects affect nostril symmetry in patients undergoing Le Fort I osteotomy with/without cinch sutures. The null hypothesis of this study was that the side of nasotracheal intubation (right or left) would not significantly affect postoperative nostril symmetry, and that no interaction would exist between intubation side and the use of alar cinch sutures in patients undergoing Le Fort I osteotomy.

Materials and methods

This retrospective study evaluated adult patients who underwent orthognathic surgery with nasotracheal intubation under general anesthesia between 2012 and 2020 at Erciyes University, Faculty of Dentistry, Department of Maxillofacial Surgery. This study was approved by the local ethics committee for Clinical Research of Erciyes University (Approval code: 2020/565) and conducted to the provisions of the Declaration of Helsinki. The records of patients were retrospectively reviewed. Informed consent was obtained from all patients included in the study for data analysis and possible publication purposes.

Inclusion and exclusion criteria

Late adolescent and adult patients (18–30 years) classified as ASA I–II and who underwent primary Le Fort I osteotomy because of dento-skeletal deformity with nasotracheal intubation were included. Pre- and post-operative (6th month) 3D stereophotogrammetric records of adequate quality were required for inclusion. Patients were excluded if they had (i) a history of unilateral or bilateral cleft lip and/or palate, (ii) revision or secondary Le Fort I osteotomy, (iii) preoperative or concomitant septoplasty or rhinoplasty, (iv) preoperative nasal inflammation, trauma, or dermal fillers affecting nasal morphology, (v) congenital midfacial deformities altering nasal symmetry, (vi) incomplete medical or imaging records.

The primary predictor variable was whether an alar cinch suture was applied (Group I vs. Group II). The side of intubation was defined as a secondary predictor variable. The classic single suture alar cinch technique was used, in which bilateral alar fibroareolar tissues were fixed together using a non-absorbable suture, and the bilateral nasal alar muscle was tightened [6, 7]. The primary outcome was the change in nostril width. The changes were assessed by comparing 3D imaging data of nostril width at T0 and T1.

Surgical technique

Nasotracheal intubation

Prior to the induction of general anesthesia, the anesthesiologist evaluated each patient's cone beam computed tomography (CBCT) coronal sections to assess the nasal

passages. The intubation side was determined by selecting the wider nasal passage to minimize nasal mucosal trauma and reduce postoperative morbidity [10]. Tube size was individually selected for each patient by the same experienced anesthesiologist based on airway assessment and patient characteristics to ensure accurate ventilation. According to intraoperative anesthesia records, nasotracheal tube sizes ranged from 6.0 to 6.5 mm in female patients and 7.0 to 7.5 mm in male patients. This standardized size selection protocol was consistently applied throughout the study period. All patients underwent nasotracheal intubation using the RAE nasotracheal tubes, which were secured to the nasal septum with a 2/0 silk suture. The tube type and fixation method were consistent in all cases, and no alternative nasotracheal tube designs were included. This standardization minimized variability related to tube design and fixation, allowing assessment of the effect of intubation side independent of tube-related confounders.

Le fort I osteotomy

The standard Le Fort I osteotomy was performed in all patients by the same experienced surgical team. In this way, thanks to the uniform surgical approach applied, operator-related variability was minimized and consistency in technique was ensured in all cases. After the local infiltration anesthesia, a mucosal incision was made by electrocautery. A full thickness mucoperiosteal flap was elevated, and the lateral walls of the maxilla, zygomatic buttress, and piriformis aperture were exposed, and the pterygomaxillary junction was identified bilaterally. The nasal mucosa was elevated, and the base of the nasal cavity was exposed. The lateral wall osteotomy was performed with piezosurgery (Mectron S.p.A., Carasco, Italy), and pterygoid plates, nasal septum, and lateral nasal walls were separated with osteotomes. The downfracture of the maxilla was performed using a hook and bone spreader after the osteotomies were completed. The maxilla was taken to its new position with the intermediate splint, and the rigid fixation was performed using miniplates and monocortical screws (KLS Martin, Tutlingen, Germany) in all patients [10].

Alar cinch suture technique

In the cinched group, the alar base cinch suture was performed using a standardized technique adapted from Collins and Epker [6]. A non-absorbable polypropylene suture (2/0 Prolene) was used in all cases. Bilateral needle passage was performed through the fibroareolar tissues at the base of each ala, ensuring symmetric engagement of the perinasal soft tissues. The suture was tightened along a horizontal medializing vector to reduce alar base width, with equal tension applied on both sides to avoid asymmetry or overcorrection. Final tightening was performed under direct visual assessment of alar symmetry, ensuring optimal symmetry before wound closure. All cinch sutures were placed by the same surgical team using an identical technique, and no modifications were made to the suture material, needle passage direction, or tightening vector during the study period.

Image acquisition and measurements

3dMD imaging system and 3dMD Vultus (3dMD, ATLANTA, GA, USA) software were used to evaluate that were taken at preoperative (T0) and at postoperative six months later (T1) after the surgery. All the 3dMD images were stored in the data. Each patient's head position was recorded with the natural head position. The 3D images of patients were captured using stereophotogrammetry (3dMD Face; 3dMD, Atlanta, GA, USA) one day prior to surgery and at least six months after, coinciding with the cephalometric films, all taken in the natural head position (NHP), centric occlusion, and with lips at rest. To achieve the NHP, patients were first encouraged to walk around and relax. They then performed a series of gradually diminishing forward and backward head movements until their heads found a balanced position. Finally, they were instructed to focus on their eye reflections in a mirror. Soft tissue nasal changes were assessed using 3dMD Vultus software, with the file format set to ".tsb."

For the initial registration, the 3D images captured before and after surgery were manually aligned, followed by use of the software's automatic registration feature for further refinement. Once the 3D images were accurately positioned, optimal facial surface areas that were unaffected by the surgery were selected, including the broadest part of the forehead, the region from the nasal root to the nasal dorsum, and the lateral sections around the exocanthion (Fig. 1). The superimpositions of the 3D images demonstrated reliability, with an average root mean square (RMS) error of 0.24 (range: 0.12–0.45), which is below the clinically acceptable threshold of 0.5 and consistent with previously employed methods [11].

All 3D stereophotogrammetric images were acquired with patients positioned in natural head position (NHP), with lips at rest and teeth in centric occlusion. For measurement standardization, the images were subsequently digitally oriented within the software by aligning the Frankfurt horizontal plane parallel to the ground. Nostril width was measured as a curvilinear contour length following the natural anatomy of the nostril rim. For each nostril, the measurement was initiated at the deepest point of the alar base (Right nostril: point c; Left nostril: e) and continued along the nostril contour through the anterior rim (Right nostril: points a and b; Left nostril: h and g) to the columellar reference point (Right nostril: point d; Left nostril: f). The total nostril width was

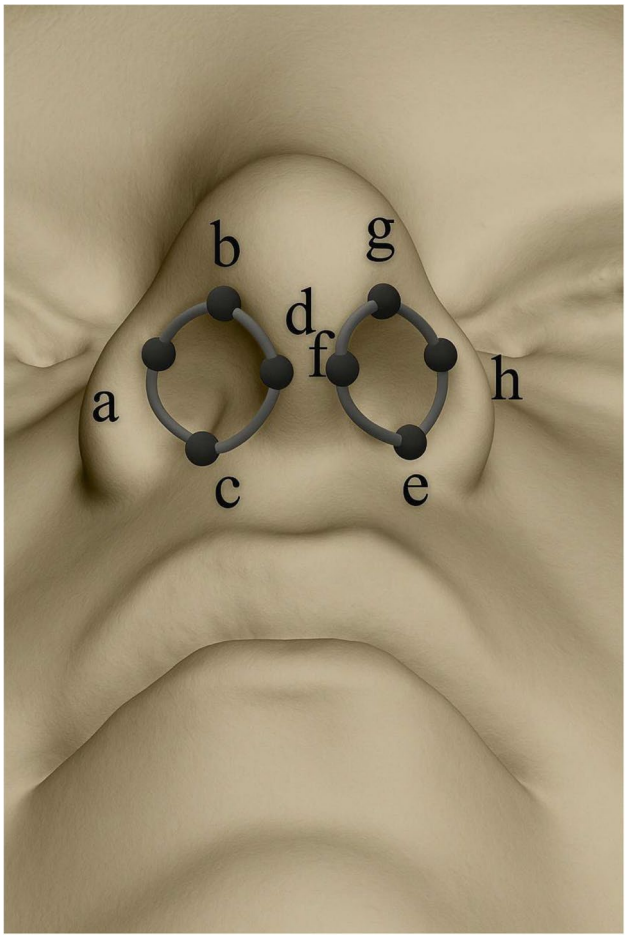

Fig. 1 Curvilinear measurement of nostril width and identification of nasal soft tissue landmarks on 3D stereophotogrammetric images. Nostril width was measured as a curvilinear contour length following the natural anatomy of the nostril rim. For each nostril, the measurement was initiated at the deepest point of the alar base and traced along the nostril contour through the anterior rim to the columellar reference point (right nostril: a–b–c–d; left nostril: e–f–g–h). The total nostril width was calculated by tracing these curved paths using the software's curved distance measurement tool

calculated by tracing this curved path (a–b–c–d; e-f-g-h) using the software's curved distance measurement tool on 3D stereophotogrammetric images. All measurements were performed using 3dMD Vultus software (3dMD, Atlanta, GA, USA). Changes in nostril width were calculated by comparing postoperative (T1) and preoperative (T0) measurements.

Sample size calculation

As a result of the two-way paired samples-t test power analysis (G*Power Version 3.1.9.6, Heinrich Heine Universität Düsseldorf, Düsseldorf, Germany) with d = 0.510, alfa = 0.05, and 1-beta = 0.856 power values performed using the study of [12], it was determined that there should be at least 37 individuals in each group.

Table 1 Descriptive statistics

	Control	Cinched	*P* values
Age (year)	23.26 ± 5.25	21.59 ± 4.38	0.094 *
Maxillary Advancement (mm)	4.33 ± 1.98	4.51 ± 2.19	0.748 *
Maxillary Impaction (mm)	1.78 ± 1.30	2.29 ± 1.85	0.226 *
Gender (Female)	24 (%55.8)	34 (%81.0)	0.013 **
Gender (Male)	19 (%44.2)	8 (%19.0)	

* Result of Independent samples-t test

** Result of Pearson Chi-Square test

Statistical analysis

The data obtained was recorded on a computer using Microsoft Excel software (Microsoft 365, Microsoft, USA). Statistical analyses were performed using JAMOVI software (Ver. 2.4.12, The Jamovi project, Sydney, Australia). The Shapiro-Wilk test was used for normality analysis of the data, and the Levene's test was used for homogeneity analysis. Paired Samples t-test was used to compare variables determined to be normally and homogeneously distributed within groups, and Independent Samples t-test was used to compare between groups. $P < 0.05$ was accepted for statistical significance. Given the statistically significant difference in gender distribution between groups (Table 1), gender was included as a covariate in the analysis of covariance (ANCOVA) model to control for its potential confounding effect on nostril width changes.

Results

A total of 612 records were evaluated, and 85 patients were included in this study, divided into a control group ($n = 43$) and a cinched suture group ($n = 42$). The demographic and surgical data for both groups are presented in Table 1. There were no statistically significant differences between the groups in terms of mean age (23.26 ± 5.25 years for control vs. 21.59 ± 4.38 years for cinched, $p = 0.094$), mean maxillary advancement (4.33 ± 1.98 mm vs. 4.51 ± 2.19 mm, $p = 0.748$), or mean maxillary impaction (1.78 ± 1.30 mm vs. 2.29 ± 1.85 mm, $p = 0.226$). However, a statistically significant difference was found in the gender distribution between the groups ($p = 0.013$), with a higher proportion of female patients in the cinched group (81.0%) compared to the control group (55.8%).

The changes in nostril width from pre-operative (T0) to post-operative (T1) are detailed in Table 2. In the control group with right-sided intubation, a statistically significant increase was observed in the right nostril width from 8.20 ± 1.14 mm to 8.77 ± 1.07 mm ($p = 0.006$). The left nostril width did not change significantly ($p = 0.286$). In the control group with left-sided intubation, a statistically significant increase was noted in the left nostril width from 7.81 ± 0.96 mm to 8.54 ± 1.27 mm ($p = 0.006$) and in the right nostril width from 7.88 ± 1.13 mm to 8.35 ± 1.23 mm ($p = 0.025$). (Fig. 2) In the cinched suture

Table 2 Comparison of nostril width measurements (mm) at T0 and T1

Groups						
Variables	**Control**					
	Right Intubation			**Left Intubation**		
	T0	**T1**	***p* values***	**T0**	**T1**	***p* values***
Nostril Width R	8.20 ± 1.14	8.77 ± 1.07	0.006	7.88 ± 1.13	8.35 ± 1.23	0.025
Nostril Width L	7.93 ± 1.16	8.10 ± 1.07	0.286	7.81 ± 0.96	8.54 ± 1.27	0.006
p values**	0.451	0.033		0.761	0.535	
Cinched						
Variables	**Right Intubation**			**Left Intubation**		
	T0	**T1**	***p* values***	**T0**	**T1**	***p* values***
Nostril Width R	8.27 ± 1.55	9.06 ± 1.15	0.010	8.16 ± 1.31	8.04 ± 1.39	0.674
Nostril Width L	8.09 ± 1.35	8.47 ± 1.25	0.038	8.09 ± 1.15	8.43 ± 1.03	0.122
p values**	0.061	0.002		0.802	0.271	

T0: Pre- operative. T1: Six-month post-operative

* Result of Paired Samples-t test

** Result of Independent Samples-t test

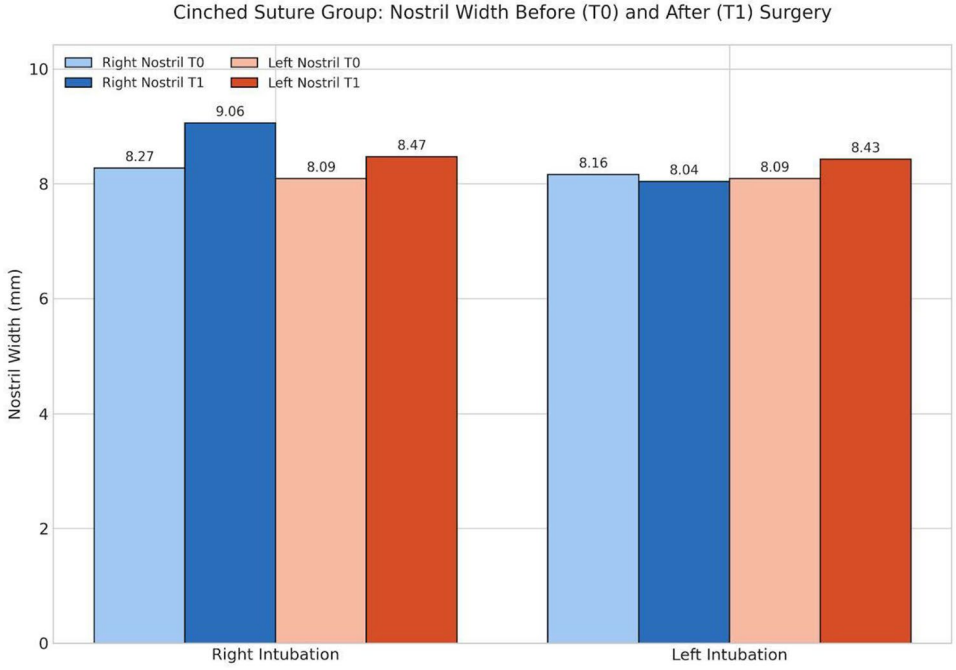

Fig. 2 Mean nostril width (mm) in the control group, comparing pre-operative (T0) and post- operative (T1) measurements. The chart displays data for both right and left nostrils, stratified by the side of nasotracheal intubation (right vs. left)

group with right-sided intubation, a statistically significant increase was measured for both the right nostril (from 8.27 ± 1.55 mm to 9.06 ± 1.15 mm, $p = 0.010$) and the left nostril (from 8.09 ± 1.35 mm to 8.47 ± 1.25 mm, $p = 0.038$). In contrast, for patients in the cinched group with left-sided intubation, no statistically significant changes were observed in either the right nostril width ($p = 0.674$) or the left nostril width ($p = 0.122$) from T0 to T1. (Fig. 3)

When the magnitude of nostril width change (Δ = T1–T0) was compared between intubation sides, the control group showed no significant differences for either the right or left nostril ($p > 0.05$, Table 3). In the cinched group, the magnitude of change in right nostril width (ΔT1–T0) was significantly greater in patients intubated on the right side compared with those intubated on the left side (0.78 ± 1.28 mm vs. −0.12 ± 1.19 mm, $p = 0.007$) (Fig. 4). No significant between-group difference was observed for changes in left nostril width ($p = 0.828$).

To account for the significant gender imbalance between groups, an analysis of covariance (ANCOVA) was performed with gender included as a covariate (Table 4). After adjustment, intubation side remained a significant predictor of right nostril width change

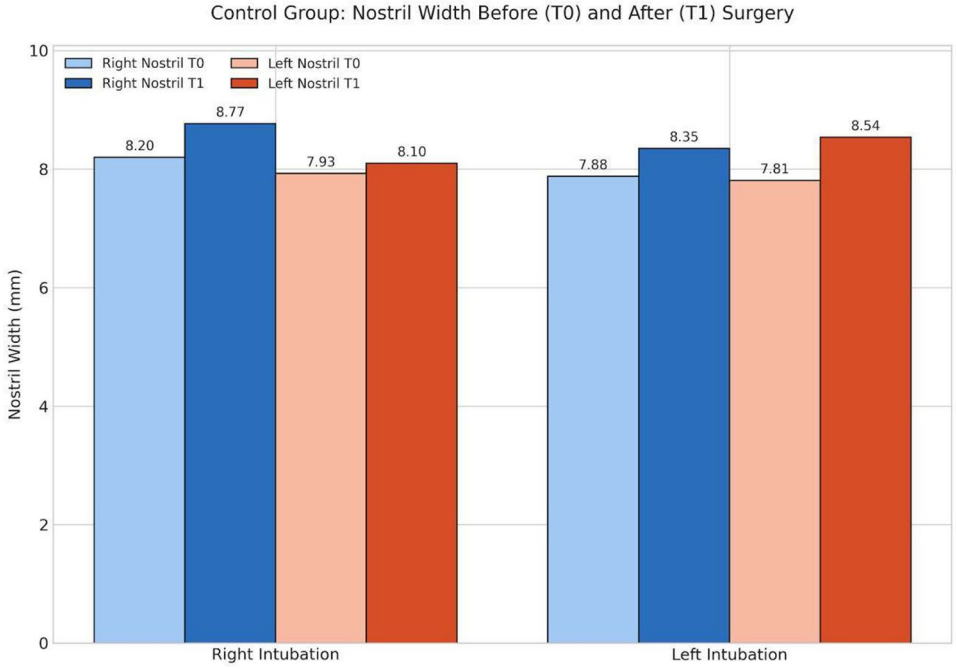

Fig. 3 Mean nostril width (mm) in the cinched suture group, comparing pre- operative (T0) and post- operative (T1) measurements. The chart illustrates the changes in both nostrils based on the side of intubation, highlighting the lack of significant widening in the left intubation subgroup

Table 3 Comparison of changes in nostril width (Δ = T1–T0, mm) between right and left nasotracheal intubation sides in the control and cinched groups

	Right Intubation	Left Intubation	*p* values**
Control			
Nostril Width R	0.57 ± 0.79	0.47 ± 0.96	0.961
Nostril Width L	0.17 ± 0.91	0.73 ± 1.17	0.126
p values**	0.136	0.409	
Cinched			
Nostril Width R	0.78 ± 1.28	-0.12 ± 1.19	0.007
Nostril Width L	0.38 ± 0.87	0.33 ± 0.84	0.828
p values**	0.088	0.170	

T0: Pre- operative. T1: Six-month post-operative

R Right, *L* Left

** Result of Independent Samples-t test

Δ indicates change between T1 and T0

(F = 4.41, $p = 0.039$, $\eta^2 p = 0.052$), whereas cinch application and gender showed no significant main effects. The interaction between cinch application and intubation side did not reach statistical significance. No significant effects were observed for left nostril width change in the adjusted model.

The adjusted estimated marginal means derived from the ANCOVA are illustrated in Fig. 5, which confirms that the observed differences are attributable to changes in nostril width (Δ values) rather than absolute postoperative measurements.

Discussion

The present study investigated the effect of nasotracheal intubation side on postoperative nostril symmetry in patients undergoing Le Fort I osteotomy, with particular emphasis on the modifying role of alar cinch suturing. The findings demonstrate that intubation side significantly influences changes in right nostril width, and that this effect persists even after adjustment for gender. Accordingly, the null hypothesis was rejected.

The Le Fort I osteotomy is a well-established procedure for the correction of dentofacial deformities; however, maxillary repositioning is known to induce undesirable nasolabial soft tissue changes, including alar flaring, nostril widening, and asymmetry [1–3, 13–15]. These changes have been attributed not only to skeletal movement but also to the extent of subperiosteal dissection and disruption of the perinasal musculature [4, 6].

Several studies have reported that the effectiveness of alar base cinch sutures in minimizing alar widening remains a subject of debate. While some studies support their use, others report no significant effects. Jung's study suggests that cinch suturing alone may not be adequate to counteract the widening effect of maxillary advancement on the nasal complex [16]. Their findings indicated that alar width increased by approximately 4 mm postoperatively, a change that was statistically significant. Conversely, Mani et al. [17] proposed that conventional alar cinch suturing can effectively control alar base widening without the need for anchorage to the anterior nasal spine. Mani et al. also concluded that anchoring sutures

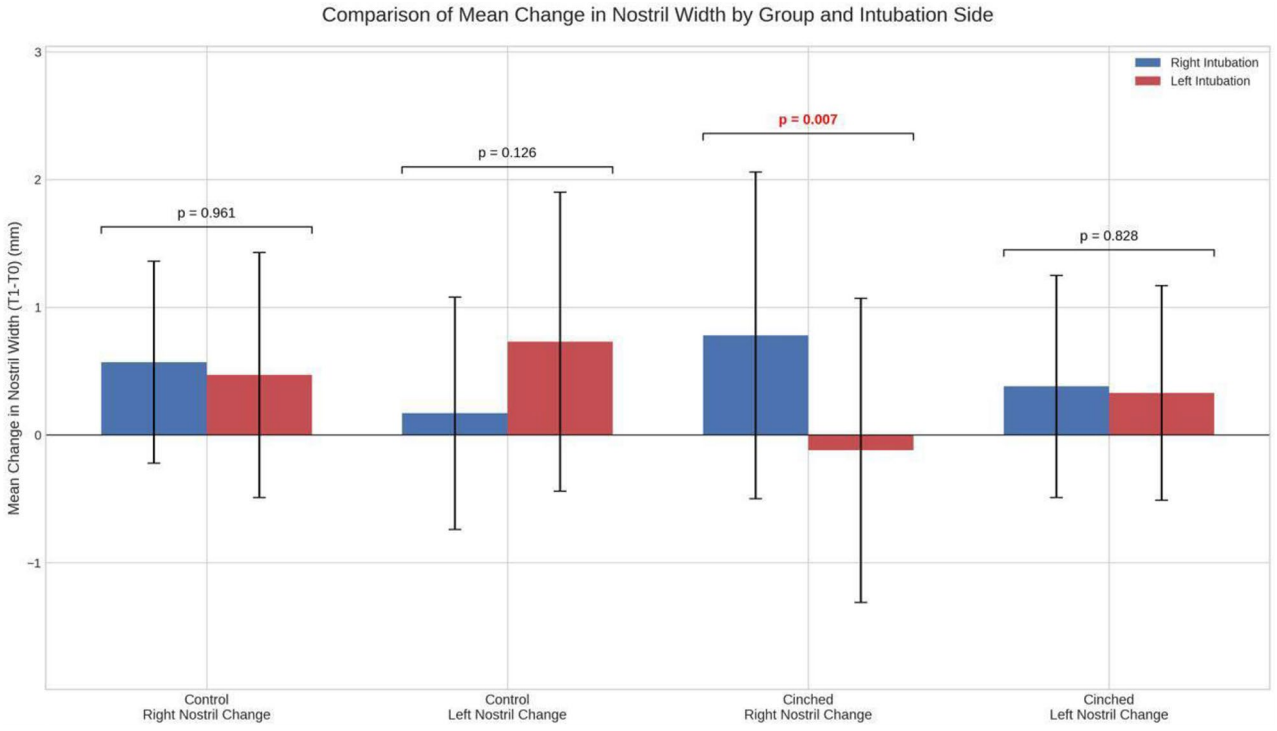

Fig. 4 Comparison of changes in nostril width (Δ = T1–T0, mm) according to intubation side in the control and cinched groups. Bars represent mean changes in nostril width for right and left nasotracheal intubation subgroups, with error bars indicating standard deviation. Between-group comparisons assess differences in the magnitude of change (ΔT1–T0) between right and left intubation sides within each group. The reported p-values refer to these between-group comparisons of change, not to absolute nostril width measurements. A statistically significant difference was observed for right nostril width change in the cinched group ($p = 0.007$)

Table 4 ANCOVA results for nostril width changes accounting for gender as a covariate

	Right Nostril Width Difference (T1-T0)				Left Nostril Width Difference (T1-T0)			
	Mean Square	**F**	***P* values**	**η^2p**	**Mean Square**	**F**	***P* values**	**η^2p**
Overall Model	2.3285	1.8474	0.128		1.138	1.59157	0.185	
Cinch application	0.7531	0.6397	0.426	0.008	0.970	1.05041	0.309	0.013
Intubation side	5.1897	4.4077	0.039	0.052	0.001	0.00104	0.974	< 0.001
Gender	0.0171	0.0146	0.904	< 0.001	2.181	2.36172	0.128	0.029
Cinch application x Intubation side	3.3541	2.8487	0.095	0.034	1.400	1.51564	0.222	0.019

T0: Pre- operative. T1: Six-month post-operative

F: Analysis of variance test statistic

P value: Statistical significance level ($p < 0.05$ considered significant)

η^2p: Partial eta squared

to the anterior nasal spine could restrict postoperative adjustments, potentially compromising the ability to fine-tune the nasal base after surgery [17].

However, nasotracheal intubation, widely used for airway management in orthognathic surgery, presents challenges in assessing nasal base width and placing cinch sutures [18]. In the literature, some authors suggest suturing after removing the intubation tube, while others propose submental intubation and transitioning from nasal to oral endotracheal tubes [7]. Some surgeons have even recommended extubation for final tightening of the cinch sutures and closure of the wound, which was disapproved by anesthesiologists.

Raithatha et al. investigated the long-term effects of the cinch suture in patients who underwent Le Fort I osteotomy using submental intubation [18]. Their study, with a 3-year follow-up, demonstrated that the cinch suture effectively reduced the alar bases to approximately their preoperative width immediately after surgery, and maintained this width with minimal long-term changes.

In orthognathic surgery, surgical management is also affected from intubation types. When oral and nasal intubation was compared, nasal intubation has been preferred due to simply access to maxillofacial region and allowing the intermaxillary fixation during the operation. Cuffed reinforced endotracheal tubes and north polar

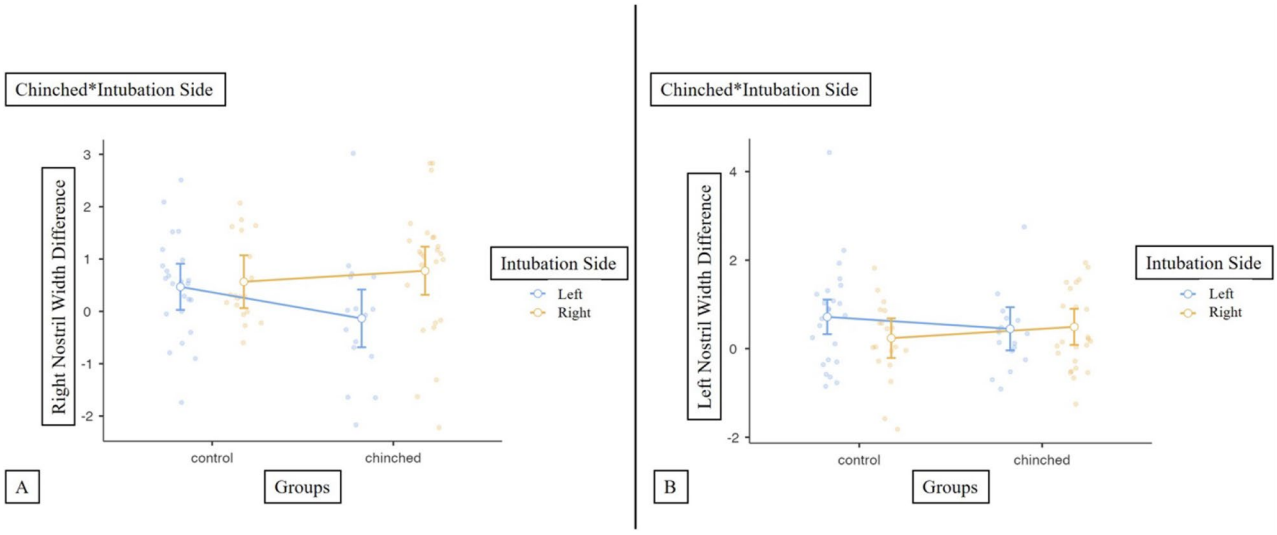

Fig. 5 Estimated marginal means of nostril width change (ΔNW = T1–T0, mm) according to cinch application (control vs. cinched) and nasotracheal intubation side (right vs. left), adjusted for gender using ANCOVA. **A** illustrates changes in right nostril width (ΔNW_R), and (**B**) illustrates changes in left nostril width (ΔNW_L). Points represent adjusted mean values, and error bars indicate 95% confidence intervals

endotracheal tubes are used for nasal intubation. According to recent studies, the type of tube will be affecting satisfying outcomes after surgery, so North Polar tube should be used for nasal intubation to have better outcomes [19]. In the present study, the RAE nasotracheal tubes were used in all cases, providing consistency in tube design and reducing potential confounding related to different tube geometries.

Submental intubation, although effective, is more invasive and may be associated with postoperative scarring. Similarly, although a modified nasal-oral endotracheal tube exchange technique has been proposed, its validity is still debated. A study evaluating this technique, with a 12-month follow-up, showed no significant difference in alar base width between the tube switch group and the control group, suggesting that this method might not offer major benefits over traditional approaches [20].

The results of the present study indicate that right-sided nasotracheal intubation (NTI), both with and without alar cinch sutures, was associated with a significant change in nostril width, whereas left-sided NTI with cinch sutures did not result in a measurable change. This asymmetry may be related to surgical ergonomics and operative positioning. In the present study, surgeons in the operating team were right-handed and routinely performed the procedure from the patient's right side. This positioning may require greater soft tissue retraction on the right side, which could contribute to postoperative changes in nostril width. Prolonged or increased retraction may, in turn, influence postoperative nostril width. In addition, although gender-related differences in nasal soft tissue thickness and elasticity have been reported, adjustment for gender in the present analysis did not alter the observed association between intubation side and postoperative nostril width changes. A crucial methodological consideration is the potential for anatomical selection bias associated with the choice of intubation side. In the present study, the side of nasotracheal intubation was not randomized but selected based on preoperative CBCT assessment of the wider nasal passage to minimize nasal trauma.

The authors acknowledge several limitations of this study. A major limitation is the absence of immediate postoperative measurements. Nasal soft tissue dimensions may be transiently affected by postoperative edema and early healing processes, which could influence the short-term manifestation of intubation-related nasal deformation. Therefore, only six-month postoperative data were analyzed to reflect more stable soft tissue outcomes after resolution of postoperative swelling. Consequently, potential short-term effects of nasotracheal intubation on nostril morphology during the immediate postoperative period could not be assessed and should be addressed in future prospective studies with early postoperative follow-up. In addition, the retrospective nature of the study design introduces inherent limitations, including the inability to control all potential confounding variables. The side of nasotracheal intubation was not randomized but selected based on preoperative CBCT evaluation of the wider nasal passage to minimize nasal trauma, which may have introduced inherent anatomical selection bias related to preexisting nasal asymmetry. As a single-center study, the results may also be influenced by local surgical protocols and surgeon-specific factors, such as operating position and handedness, which may limit the generalizability of the findings. Finally, the

absence of a comparison group using alternative airway management techniques that avoid the presence of a nasotracheal tube during wound closure represents another limitation. Inclusion of approaches such as submental intubation, as described by Raithatha et al. [17], or nasal-to-oral tube switching techniques, as investigated by Shaik et al. [20], could have allowed a more direct evaluation of the isolated effect of the alar cinch suture without the confounding physical presence of a nasotracheal tube.

Conclusion

This study is the first in the literature to demonstrate that the side of nasotracheal intubation (NTI) may influence postoperative nostril symmetry, highlighting a previously underrecognized factor affecting aesthetic outcomes after Le Fort I osteotomy. Although changes in nostril dimensions are inherently related to maxillary repositioning, the present findings suggest that the physical presence of a nasotracheal tube during wound closure may mechanically influence alar base positioning, an effect that may not be fully mitigated by conventional alar cinch suturing. Right-sided intubation was associated with a more pronounced increase in nostril width, potentially influenced by surgical ergonomics and operative positioning.

Based on these observations, we hypothesize that the effectiveness of alar cinch suturing may be enhanced when final tightening is performed in the absence of nasal deformation caused by the intubation tube. However, this concept should be regarded as hypothesis-generating, as the retrospective design of the present study did not include patients managed after extubation. Any modification to the timing of cinch suture placement must therefore be carefully balanced against airway safety considerations and anesthetic feasibility.

Rather than recommending routine cinch suturing after extubation, the present findings underscore the need for further investigation into alternative airway management strategies that allow unobstructed access to the alar base while maintaining airway control. In this context, switching from nasotracheal to orotracheal intubation after completion of maxillary fixation but prior to alar cinch suturing may be considered as a potential approach, as it avoids the presence of a nasal tube during wound closure and may be less invasive and potentially safer than submental intubation. In addition, meticulous soft tissue handling, gentle dissection, and avoidance of excessive retraction—particularly related to the intubation tube—remain essential to preserving nostril symmetry.

Future prospective, multicenter randomized controlled trials are warranted to validate these findings and to further clarify the interplay between surgical technique, airway management, and final aesthetic outcomes in orthognathic surgery.

Abbreviations

ASA	American Society of Anesthesiologists physical status classification
NW	Nostril width
3D	Three-dimensional
3dMD	3dMD stereophotogrammetry imaging system
CBCT	Cone beam computed tomography
RMS	Root mean square error
T0	Preoperative time point
T1	Postoperative six-month time point
NHP	Natural head position
mm	Millimeter
NTI	Nasotracheal intubation
RAE tube	Ring–Adair–Elwyn nasotracheal tube

Acknowledgements

This study was presented as an oral presentation at the 17th International Congress of ACBID, held between 10 and 14 May 2024 in Antalya, Türkiye. The authors acknowledge the use of ChatGPT (OpenAI, San Francisco, CA, USA) for assistance with English language editing and proofreading. The authors take full responsibility for the content of the manuscript.

Authors' contributions

Conceptualization and project administration: Emrah Soylu; Methodology and validation: Emrah Soylu, Selin Çelebi, Begüm Yener, Taner Öztürk, and Gökhan Çoban; Supervision: Emrah Soylu and Ahmet Emin Demirbaş; Data curation and investigation: Selin Çelebi, Begüm Yener, Seher Orbay Yaşlı and Dilek Günay Canpolat; Formal analysis: Taner Öztürk; Resources and software: Ahmet Emin Demirbaş, Seher Orbay Yaşlı and Dilek Günay Canpolat; Writing—original draft: Emrah Soylu, Selin Çelebi, Begüm Yener, and Taner Öztürk; Writing—review and editing: Emrah Soylu, Taner Öztürk, Gökhan Çoban, and Ahmet Emin Demirbaş. All authors have read and approved the final version of the manuscript and agree to be accountable for all aspects of the work.

Funding

This research did not receive any specific grant from funding agencies in the public, commercial, or not-for-profit sectors.

Data availability

The datasets used and/or analyzed during the current study are available from the corresponding author on reasonable request.

Declarations

Ethics approval and consent to participate

The study was approved by the Erciyes University Clinical Research Ethics Committee (Approval Code: 2020/565) and conducted to the provisions of the Declaration of Helsinki. Informed consent was obtained from all patients included in the study for data analysis and possible publication purposes.

Consent for publication

Not applicable.

Competing interests

The authors declare no competing interests.

Author details

[1]Erciyes University Faculty of Dentistry, Department of Oral and Maxillofacial Surgery, Kayseri 38039, Türkiye
[2]DentBioChem Biotechnology Inc., Erciyes Teknopark, 38039 Kayseri, Türkiye
[3]Private Practice, Kayseri 38039, Türkiye
[4]Erciyes University Faculty of Dentistry, Department of Orthodontics, Kayseri 38039, Türkiye

Received: 18 November 2025 / Accepted: 26 December 2025
Published online: 05 January 2026

References

1. Mansour S, Burstone C, Legan H. An evaluation of soft-tissue changes resulting from Le fort I maxillary surgery. Am J Orthod. 1983;84(1):37–47. https://doi.org/10.1016/0002-9416(83)90146-x.
2. Dantas WR, Silveira MM, Vasconcelos BC, Porto GG. Evaluation of the nasal shape after orthognathic surgery. Braz J Otorhinolaryngo. 2015;81(1):19–23. https://doi.org/10.1016/j.bjorl.2014.08.005.
3. Paredes deS, Gil A, Guijarro-Martínez R, Haas OL, Hernández-Alfaro J, F. Three-dimensional analysis of nasolabial soft tissue changes after Le fort I osteotomy: a systematic review of the literature. Int J Oral Maxillofac Surg. 2019;48(9):1185–200. https://doi.org/10.1016/j.ijom.2019.01.028.
4. Rauso R, Gherardini G, Santillo V, Biondi P, Santagata M, Tartaro G. Comparison of two techniques of cinch suturing to avoid widening of the base of the nose after Le fort I osteotomy. Br J Oral Maxillofac Surg. 2010;48(5):356–9. https://doi.org/10.1016/j.bjoms.2009.08.007.
5. Millard DR Jr. The Alar cinch in the flat, flaring nose. Plast Reconstr Surg. 1980;65(5):669–72. https://doi.org/10.1097/00006534-198005000-00020.
6. Collins PC, Epker BN. The Alar base cinch: a technique for prevention of Alar base flaring secondary to maxillary surgery. Oral Surg Oral Med Oral Pathol. 1982;53(6):549–53. https://doi.org/10.1016/0030-4220(82)90338-3.
7. Rauso R, Tartaro G, Nicoletti GF, Fragola R, Lo Giudice G, Santagata M. Alar cinch sutures in orthognathic surgery: scoping review and proposal of a classification. Int J Oral Maxillofac Surg. 2022;51(5):643–50. https://doi.org/10.1016/j.ijom.2021.10.003.
8. Werther JR, Richardson G, McIlwain MR. Nasal tube switch: converting from a nasal to an oral endotracheal tube without extubation. J Oral Maxillofac Surg. 1994;52(9):994–6. https://doi.org/10.1016/s0278-2391(10)80090-4.
9. Ryoo SH, Park KN, Karm MH. The utilization of video laryngoscopy in nasotracheal intubation for oral and maxillofacial surgical procedures: a narrative review. J Dent Anesth Pain Med. 2024;24(1):1–17. https://doi.org/10.17245/jdapm.2024.24.1.1.
10. Soylu E, Kılavuz MS, Eren C, Demirbas AE, Kaba YN, Kütük N, Kılıç E, Etöz OA, Alkan A. Understanding Re-operation in orthognathic surgery: A 17-year retrospective study analyzing causes and rates. J Craniomaxillofac Surg. 2025;53(7):977–82. https://doi.org/10.1016/j.jcms.2025.03.010.
11. Lin HH, Chiang WC, Lo LJ, Sheng-Pin Hsu S, Wang CH, Wan SY. Artifact-resistant superimposition of digital dental models and cone-beam computed tomography images. J Oral Maxillofac Surg. 2013;71(11):1933–47. https://doi.org/10.1016/j.joms.2013.06.199.
12. Axllar ML, Movahed R, Wolford LM, Oliver DR, Harrison SD, Thiesen G, Kim KB. Nasolabial changes following double jaw surgery. J Craniofac Surg. 2019;30(8):2560–4. https://doi.org/10.1097/SCS.0000000000005876.
13. Suzen M, Dilaver E, Ak KB, Uckan S. Analysis of inferior nasal morphology and nostrils following Le fort I osteotomy. J Craniofac Surg. 2022;33(8):2682–7. https://doi.org/10.1097/SCS.0000000000008829.
14. Chung C, Lee Y, Park KH, Park SH, Park YC, Kim KH. Nasal changes after surgical correction of skeletal class III malocclusion in Koreans. Angle Orthod. 2008;78(3):427–32. https://doi.org/10.2319/041207-186.1.
15. Honrado CP, Lee S, Bloomquist DS, Larrabee Jr WF. Quantitative assessment of nasal changes after maxillomandibular surgery using a 3-dimensional digital imaging system. Arch Facial Plast Surg. 2006;8(1):26–35. https://doi.org/10.1001/archfaci.8.1.26.
16. Jung J, Lee CH, Lee JW, Choi BJ. Three dimensional evaluation of soft tissue after orthognathic surgery. Head Face Med. 2018;14(1):21. https://doi.org/10.1186/s13005-018-0179-z.
17. Mani V, Panicker P, Shenoy A, George AL, Chacko T. Evaluation of changes in the Alar base width following Lefort 1 and AMO with conventional Alar cinch suturing: A photographic study of 100 cases. J Maxillofac Oral Surg. 2020;19(1):21–5. https://doi.org/10.1007/s12663-019-01227-8.
18. Raithatha R, Naini FB, Patel S, Sherriff M, Witherow H. Long-term stability of limiting nasal Alar base width changes with a cinch suture following Le fort I osteotomy with submental intubation. Int J Oral Maxillofac Surg. 2017;46(11):1372–9. https://doi.org/10.1016/j.ijom.2017.04.027.
19. Öztürk Muhtar M, Yey Özkeskin SZ, Kara YB, Dincer C, Cansız P. E., 2025. Impact of nasal intubation tube design on nasal morphology in orthognathic surgery: a comparative study. J Maxillofac Oral Surg. 2025 (Epub of ahead). https://doi.org/10.1007/s12663-025-02702-1.
20. Shaik TNS, Meka S, Ch PK, Kolli NND, Chakravarthi PS, Kattimani VS, Prasad K, L. Evaluation of modified nasal to oral endotracheal tube switch-For modified Alar base cinching after maxillary orthognathic surgery. J Oral Biol Craniofac Res. 2017;7(2):75–80. https://doi.org/10.1016/j.jobcr.2017.03.008.

Publisher's note

Springer Nature remains neutral with regard to jurisdictional claims in published maps and institutional affiliations.