European Journal of Orthodontics, 2015, 164–169
doi:10.1093/ejo/cju028
Advance Access publication July 4, 2014

Original article

Effect of St John's wort on bone formation in the orthopaedically expanded premaxillary suture in rats: a histological study

Koray Halicioglu*, Bayram Çörekçi*, İsmail Akkaş, Celal Irgin*, Fatih Özan**, Fahri Yilmaz*** and Arzu Türker******

*Departments of Orthodontics and **Oral and Maxillofacial Surgery, Faculty of Dentistry, ***Department of Pathology, Faculty of Medicine, ****Department of Biology, Faculty of Arts and Science, Abant İzzet Baysal University, Bolu, Turkey

Correspondence to: Koray Halicioğlu, Department of Orthodontics, Faculty of Dentistry, Abant İzzet Baysal University, 14280 Bolu, Turkey. E-mail: korayhalicioglu@hotmail.com or koray.halicioglu@ibu.edu.tr

Summary

Background/Objective: The aim of this study was to investigate the effect of systemic St John's wort (*Hypericum perforatum*) on bone formation in the expanded premaxillary suture in rats.
Materials/Methods: A total of 28 rats were randomly divided into four groups of equal numbers: control (C); only expansion (OE); St John's wort extract given only during the expansion and retention period (a total of 17 days; SJW group); and St John's wort extract given during the nursery phase before expansion (a period of 40 days), and during the expansion and retention periods (a total of 57 days; N + SJW group). After the 5 day expansion period was completed, the rats in the OE, SJW, and N + SJW groups underwent 12 days of mechanical retention, following which they were killed, and their premaxilla dissected and fixed. Histological examination was performed to determine the number of osteoclasts and capillaries, as well as the number of osteoblasts, inflammatory cell infiltration, and the amount of new bone formation.
Results: Statistical analysis showed that the number of osteoclasts and capillaries, and the inflammatory cell infiltration, as well as new bone formation, were higher in the SJW and N + SJW groups than in the other groups. However, statistical analysis demonstrated that among these two groups, all parameters, with the exception of the number of capillaries, were higher in the N + SJW group than the SJW group.
Conclusions/Implications: Although more effective in long-term usage, systemic use of St John's wort hastens new bone regeneration at the premaxillary suture and may help prevent relapse after expansion.

Introduction

Expansion of the mid-palatal suture is an indispensable procedure for orthodontic specialists in the correction of malocclusions on the transverse dimension. It rapidly increases the transverse width of the upper dental arch at the apical base and includes an active phase, with expansion appliances to disarticulate the neighbouring jaw bones by rupture as a result of widening the mid-palatal suture, and a passive phase, bone remodelling of the mid-palatal suture (1).

However, relapse after rapid maxillary expansion is inevitable, and this is a multi-factorial phenomenon (2–4). Although the real causes of relapse tendency are not yet precisely understood, investigators (5–15) have emphasized the fact that velocity and quality of new bone formation in the mid-palatal suture after expansion affect post-expansion

© The Author 2014. Published by Oxford University Press on behalf of the European Orthodontic Society. All rights reserved.
For permissions, please email: journals.permissions@oup.com

Downloaded from https://academic.oup.com/ejo/article/37/2/164/2570544 by Erciyes University user on 01 February 2022

relapse. They used new materials and methods and confirmed an effect on accelerating new bone formation at the expanded suture. Some of these studies (5, 7, 8, 14, 15) showed that antioxidants affect bone metabolism, via an increase of osteoblastic activity.

St John's wort (*Hypericum perforatum*) is native to Europe, West Asia, and North Africa, and it has been naturalized to USA and Australia. It is emphasized as having sedative and astringent properties, and has been traditionally used for the treatment of excitability, neuralgia, fibrositis, sciatica, menopausal neurosis, anxiety, and depression, as well as a nerve tonic, and in topical preparations for the treatment of wounds (16, 17). Nowadays, it is widely used in herbal products, as well as in homoeopathic preparations, and is also used in foods as flavouring. St John's wort is categorized by the Council of Europe as a natural source of food flavouring (category 5) (18) and, furthermore, its extracts have become popular natural medicines for the treatment of mild-to-moderate depression (16). In addition to all of these, there are no doubts that the chemical of many constituents of St John's wort possess and easily explain antioxidant properties (19). St John's wort consists of a variety of active components, including flavonoids. Although flavonoids have not been implicated in the antidepressant actions of St John's wort, they do play a key role in its other therapeutic effects. Flavonoids were shown to have potent antioxidant activity. Therapeutically, the fact that this popular herb has antioxidant properties is an added bonus to its clinical effects as an antidepressant (20).

The aim of this experimental study was to evaluate the effects of long- and short-term systemic usage of St John's wort on bone formation in the expanded premaxillary suture in a rat model. This study is also of added importance, as is it was the first to assess the effects of St John's wort on bone formation.

Materials and methods

We obtained a cohort of 28 adult male Wistar albino rats (aged 12 weeks, average weight 200 ± 10 g) from the research centre of experimental animals at Abant İzzet Baysal University, Faculty of Medicine, Bolu, Turkey. The rats were housed separately in plastic cages under artificial lighting from fluorescent lamps, with a 12 hour light photoperiod and a 12 hour dark photoperiod. The temperature of the cages was set at 25°C, and food and water were provided *ad libitum*.

This study was approved by the local ethical committee of animal research of Abant İzzet Baysal University (2012/46) and was carried out in accordance with the guidelines for the use of laboratory animals.

The 28 rats were randomly divided into four groups of equal numbers (n = 7) as follows:

1. Control (C) group,
2. Only expansion (OE) group (a total of 17 days with retention period),
3. St John's wort extract given only during the expansion and retention period (a total of 17 days; SJW group) and
4. St John's wort extract given during their nursery phase before expansion (a period of 40 days), and during the expansion and retention period (a total of 57 days; N + SJW group).

Plant material and extract preparation

Hypericum perforatum L. (St John's wort) was collected from Sivas, Turkey in June 2012, and identification of species was made by using 'Flora of Turkey and the East Aegean Islands' (21). The aerial parts of the plant were dried in a room, avoiding sunlight, and then ground into a powder. A total of 40 g of powdered plant material were extracted with 400 ml distilled water at 45°C in a water bath for 18 hours and then filtered. Frozen filtrate was lyophilized by using a freeze-dryer at −65°C. The final yield of crude extract was 6.1 g. Lyophilized extract was dissolved in sterile distilled water, in order to obtain a final concentration of 30 mg/ml.

St John's wort extract was administered to the SJW and N + SJW groups at a dose of 0.7 ml/day, via orogastric tubes.

Expansion appliance and expansion and retention procedure

The expansion appliance comprised helical springs fabricated from 0.012 in. stainless steel wires. The helical springs were placed on a grid and activated on a single arm with pliers. The force was measured with a gauge (30 g), and the springs were not reactivated during the expansion period. Expansion springs were attached to the maxillary incisor of all rats under anaesthesia (xylasine + ketamine combination, 0.5 and 1 ml/kg intramuscular, respectively). A hole was drilled in both incisors at the same level, and the prepared springs inserted into the holes from the buccal side. The expansion procedure was completed for a period of 5 days in all the rats. In addition, occlusal radiographs were taken at the end of the expansion procedure in order to verify orthopaedic expansion. It was observed that the premaxillary suture was successfully expanded in all the expansion groups. In the OE, SJW and N + SJW groups, the helical springs were removed after the expansion procedure, and a piece of rectangular retaining wire was inserted for retention (Figure 1). These rats underwent 12 days of mechanical retention.

Specimen preparation

As soon as the necessary procedure was completed for all groups, the animals were killed, and then their premaxilla were dissected and placed in bottles containing 10 per cent formalin. After fixation, the retaining wires were removed, and the premaxilla was decalcified with 5 per cent formic acid for 3 days. The decalcifying solutions were changed two or three times a day during decalcification.

The maxillary incisors acted as the essential guide for orienting the sections. The section was cut perpendicular to the sagittal plane and was determined by two points, one at the alveolar crest and the other 4 mm apically. This plane passed through the centre of the incisor crown at its gingival portion. The sections were rinsed, trimmed, and embedded in paraffin. The paraffin blocks were sliced into 5 µm thick sections, and prepared for haematoxylin and eosin staining before optical microscope examination.

Histological evaluation was performed by two examiners blinded to the identity of the sections, and the average of the counts was obtained. Three histologic sections from each animal were analysed. The study and control groups were compared to establish the number of osteoclasts, osteoblasts, and capillaries, as well as the intensity of inflammatory cells, and new bone formation. The sections were rated as mild (+: 0–15 cells), moderate (++: 15–30 cells) or strong (+++: >30 cells) for capillary intensity. However, new bone formation and inflammatory cell infiltration were qualitative features and were evaluated in a subjective manner [mild: + (score 1); moderate: ++ (score 2) or strong: +++(score 3)].

Statistical analysis

All statistical analyses were performed using the SPSS software package for Windows (version 15.0, SPSS, Chicago, Illinois, USA). The difference was considered to be statistically significant at $P < 0.05$.

Downloaded from https://academic.oup.com/ejo/article/37/2/164/2570544 by Erciyes University user on 01 February 2022



Figure 1. Occlusal radiographs of the expanded premaxillary suture at the beginning of the retention.

Differences in the number of osteoclasts and capillaries among the four groups were evaluated with the use of the Kruskal–Wallis test, and the results were presented as the mean ± standard deviation. Pairwise comparisons were made with the use of the Mann–Whitney *U*-test.

The parameters relating to the number of osteoblasts, inflammatory cell infiltration, and new bone formation were represented as the scores indicating intensities. The scores of the groups were compared using Fisher's exact test.

Results

Number of osteoclasts

The lowest number of osteoclastic cells was found in the C (non-expansion, control group) group (1.79 ± 0.48), which represented the physiological situation. The number of osteoclasts was significantly higher in the N + SJW and SJW groups than in the OE group ($P < 0.01$), indicating the increased activity. However, the Mann–Whitney *U*-test showed that this parameter was statistically significantly higher in the N + SJW group (8.80 ± 0.80) than in the SJW group (6.71 ± 0.46, $P < 0.05$; Tables 1 and 2; Figure 2).

Number of capillaries

The SJW and N + SJW groups showed a significant increase in the number of capillaries relative to the other groups ($P < 0.05$ and $P < 0.001$). However, the Mann–Whitney *U*-test demonstrated that the number of capillaries was similar in the N + SJW and SJW groups (Tables 1 and 2; Figure 2).

Number of osteoblasts

The histological findings revealed that the number of osteoblasts was significantly higher in the N + SJW and SJW groups than the other groups, indicating the increased activity ($P < 0.01$; Table 3; Figure 2).

Inflammatory cell infiltration and new bone formation

Inflammatory cell intensity was significantly higher in the N + SJW group than in the other groups ($P = 0.017$). However, when the groups were compared on the basis of new bone formation, considerable differences were found among the groups. The results showed that the increase in new bone formation in the N + SJW group was significantly greater than that observed in the other groups ($P = 0.001$; Table 3; Figure 2).

Discussion

Adolescent patients more often undergo orthodontics treatment. Nevertheless, adolescents may be extremely sensitive to social successes and/or failures. The latter can often lead to psychiatric problems, such as depression, anxiety disorders, and oppositional defiant/conduct disorders (22, 23). Cassidy and Jellinek (24) reported that psychiatric disorders occur in 14–20% of US children and adolescents. Randomized controlled trials have shown that high-quality *Hypericum* extracts are more effective than placebo and similarly effective to standard antidepressants (25, 26), and these extracts are prescribed in patients with mild-to-moderate symptoms (27) St John's wort extract is strictly antioxidant (19), and it is generally accepted that antioxidants accelerate new bone formation (5, 7, 8, 14, 15). However, the possible effect in patients who have undergone orthodontic treatment while taking this drug remains unknown.

Although studies (5, 7, 8, 14, 15) designed with the aim of increasing and accelerating new bone formation with use of antioxidants after sutural expansion have increased in recent years, no study has been carried out to investigate systemic St John's wort on bone formation in the expanded premaxillary suture, to date. Therefore, this study investigated the possible effects of systemic St John's wort on bone formation in the expanded premaxillary suture in rats. To our knowledge, it is the first to report the positive effects of St John's wort intake. In addition, this study is the first in which the effects of long-term use of antioxidants have been investigated.

There is a remarkable interest in animal models of bone healing because this type of research cannot be conducted on humans for ethical reasons (10). Therefore, rats were used in this study because the rat model of maxillary expansion is well established; Saito and Shimizu (28) reported that rats and rabbits are considered to be suitable for animal models designed to achieve a clear picture of bone and sutural changes under stress. However, rats have been more often used in recent studies (5–8, 13–15) of bone formation in the expanded premaxillary suture.

Previous studies have revealed that light forces of up to 20 g could produce orthodontic tooth movement without the opening of the premaxillary suture (29). However, Kara *et al.* (7) informed that continuous heavier forces cause necrosis of the periodontal ligament and hyalinized areas of the alveolar bone, and prohibit tooth movement, leading to sutural opening by the residual forces. Therefore, approximately 30 g expansion forces were used in this study, as in similar previous rat studies (5, 7, 8, 11). In addition, many investigators (7, 8, 11) have clearly defined that the 5 day expansion period is sufficient to allow premaxillary sutural opening in rats, with 30 g forces. Therefore, the distance between the maxillary incisors was not measured in this study, but occlusal radiographs were taken at the end of the expansion procedure, in order to verify orthopaedic opening, and was observed in the whole rats.

Although good tolerability has been considered a relevant advantage of *Hypericum* extracts, an increasing number of adverse effects

Downloaded from https://academic.oup.com/ejo/article/37/2/164/2570544 by Erciyes University user on 01 February 2022

Table 1. Effects of St John's wort on the number of osteoclasts and capillaries at the end of experimental period. C, non-expansion group; OE, only expansion group; SJW, St John's wort administered during expansion and retention period; N + SJW, St John's wort administered during nursery plus expansion plus retention; SD, standard deviation.

	C	OE	SJW	N + SJW	
	Mean ± SD	Mean ± SD	Mean ± SD	Mean ± SD	*P*
No. of osteoclasts	1.79 ± 0.48	2.95 ± 0.94	6.71 ± 0.46	8.80 ± 0.80	0.000
No. of capillaries	3.98 ± 0.46	7.65 ± 0.96	8.24 ± 0.68	11.19 ± 1.25	0.000

Kruskal–Wallis variant analysis: $***P < 0.001$.

Table 2. Pairwise comparisons of the groups. C, non-expansion group; OE, only expansion group; SJW, St John's wort administered during expansion and retention period; N + SJW, St John's wort administered during nursery plus expansion plus retention.

	C – OE	C – SJW	C – N + SJW	OE – SJW	OE – N + SJW	SJW – N + SJW
No. of osteoclasts	0.002**	0.002**	0.002**	0.002**	0.002**	0.002*
No. of capillaries	0.002**	0.002**	0.002**	0.035*	0.002**	0.002

Mann–Whitney *U*-test: $*P < 0.05$; $**P < 0.01$.

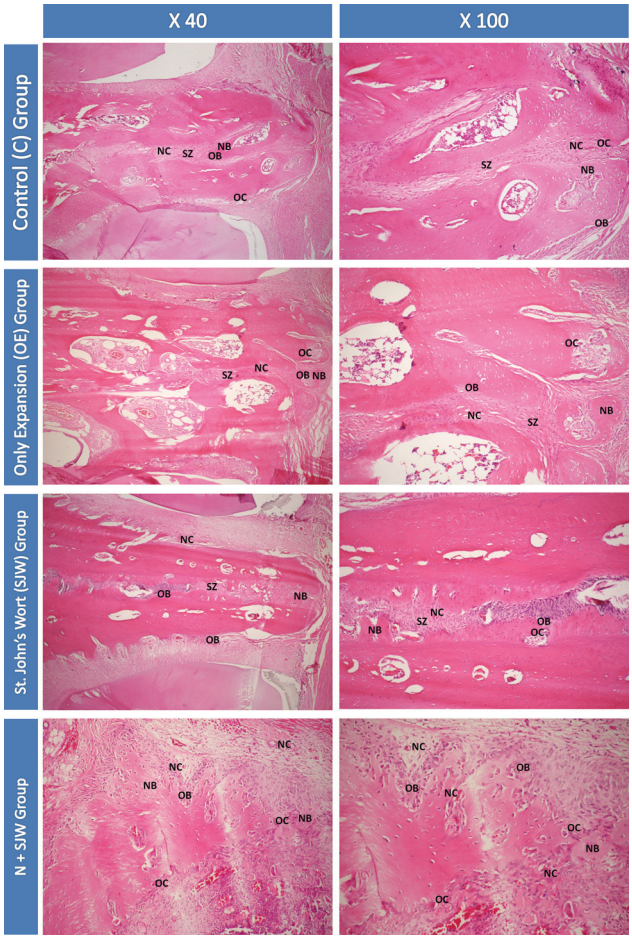

Figure 2. Haematoxylin and eosin staining photomicrographs from the study groups. OB, osteoblast; OC, osteoclast; NB, new bone; NC, new capillary; SZ, premaxillary suture zone.

have been reported, primarily relating to interactions with other drugs (27, 30, 31). Demiroglu *et al.* (32) reported a rare unfortunate case of bone marrow necrosis in a patient who had been taking St John's wort for the treatment of depression at a dose of approximately 1000 mg/day for 3 weeks. However, after meta-analysis, Knüppel and Linde (27) reported that the available evidence suggests that *Hypericum* is well-tolerated and safe if taken under the guidance of a physician who is aware of potentially relevant risks in specific circumstances. In addition, Bray *et al.* (33) administered St John's wort extract at a dose of 140 mg/kg in their animal study. Therefore, St John's wort extract doses of approximately 100 mg/kg were given to rats in this study.

The effect of St John wort on bone formation was investigated histologically in this study. The effects of *Ginkgo biloba* (7), propolis (5) and thymoquinone (8), which have antioxidant properties, on bone formation in the expanded premaxillary suture expansion of the rats were evaluated histologically. Therefore, our specimens were evaluated histologically to compare them with these previous results (5, 7, 8). The results of this study indicated that the number of osteoblasts and, accordingly, the amount of new bone formation were increased in the SJW and N + SJW groups, relative to the other groups. Elghazaly *et al.* (34) reported that St John's wort extract offers a therapeutic potential for bone, which was comparable to traditional antidepressants, such as fluoxetine or clomipramine, in irradiated female rats, and these results support those of this study. The action mechanism of St John's wort is believed to involve inhibition of serotonin reuptake, much like the selective serotonin reuptake inhibitors antidepressants (SSRIs) (35). Due to its SSRIs mechanism of action, St John's wort could not increase serum osteocalcin level (36). Elghazaly *et al.* (34) reported that markers of bone resorption as urinary hydroxyproline/creatinine ratio and urinary calcium/creatinine ratio were significantly decreased after St John's wort treatment; this could be attributed to the significant improvements in serum levels of T4, thyroid-stimulating hormone, corticosterone and tumour necrosis factor-α compared to control group. Besides its antistressful (37) and anti-inflammatory properties (38), St John's wort has a powerful antioxidant activity, showed in the Elghazaly *et al.*'s study (34) by normalizing serum total antioxidant capacity as well as malondialdehyde level. Crockett *et al.* (39) returned this powerful antioxidant property xanthones content, while Sánchez-Reus *et al.* (40) returned that to quercetin contents. We also found that the number of osteoclasts was higher in the SJW and N + SJW groups.

Downloaded from https://academic.oup.com/ejo/article/37/2/164/2570544 by Erciyes University user on 01 February 2022

Table 3. Effects of St John's wort on the number of osteoblast, inflammatory cell infiltration, and new bone formation scores indicate the number of subject animals representing that score. C, non-expansion group; OE, only expansion group; SJW, St John's wort administered during expansion and retention period; N + SJW, St John's wort administered during nursery plus expansion plus retention.

	Number of osteoblast			Inflammatory cell infiltration			New bone formation		
	Score 1	Score 2	Score 3	Score 1	Score 2	Score 3	Score 1	Score 2	Score 3
C	6	1	0	6	1	0	7	0	0
OE	2	4	1	2	4	1	2	4	1
SJW	2	5	0	1	5	1	1	4	2
N + SJW	0	5	2	0	4	3	0	3	4
P	0.018*			0.017*			0.001**		

Fisher's exact test: $*P < 0.05$; $**P < 0.01$.

This elevation in the number of osteoclasts is most likely related to the acceleration of bone turnover. When compared with previous studies (5, 7, 8), the change in the number of osteoblasts, osteoclasts and capillaries was similar in this study. When we generally evaluate these studies together with our results, we can say that *G.biloba* (7), thymoquinone (8) and propolis (5) have a similar antioxidant capacity to St John's wort when used over a period of 17 days (expansion and retention). In addition, this study was the first to investigate the effects of long-term use of antioxidants on bone regeneration. It was clearly shown that the acceleration of bone turnover demonstrated a greater increase with St John's wort use before expansion procedure. This may be the most important result of this study. However, we think that from the data provided, it is impossible to conclude that St John's wort is the sole cause for effects seen including the all observed changes.

This study was the first to present data indicating that the systemic administration of St John's wort, in conjunction with rapid maxillary expansion, may increase the quality of regenerated bone. Above all, we can say that systemic administration of St John's wort may be useful in the prevention of relapse following rapid maxillary expansion.

Conclusions

These findings suggest that systemic administration of St John's wort extract can stimulate bone regeneration in an orthopaedically expanded premaxillary suture, during expansion and retention periods. This stimulation increases with long-term use before expansion. However, further investigations about tooth movement of St John's wort could be performed.

References

1. Bishara, S.E. and Staley, R.N. (1987) Maxillary expansion: clinical implications. *American Journal of Orthodontics and Dentofacial Orthopedics*, 91, e3–e14.
2. Krebs, A.A. (1959) Expansion of midpalatal suture studied by means of metallic implants. *Acta Odontologica Scandinavica*, 17, 491–501.
3. Halicioğlu, K., Kiliç, N., Yavuz, İ. and Aktan, B. (2010) Effects of rapid maxillary expansion with a memory palatal split screw on the morphology of the maxillary dental arch and nasal airway resistance. *European Journal of Orthodontics*, 32, 716–720.
4. Halicioğlu, K. and Yavuz, I. (2014) Comparison of the effects of rapid maxillary expansion caused by treatment with either a memory screw or a Hyrax screw on the dentofacial structures–transversal effects. *European Journal of Orthodontics*, 36, 140–149.
5. Altan, B.A., Kara, I.M., Nalcaci, R., Ozan, F., Erdogan, S.M., Ozkut, M.M. and Inan, S. (2013) Systemic propolis stimulates new bone formation at the expanded suture: a histomorphometric study. *The Angle Orthodontist*, 83, 286–291.
6. Ekizer, A., Uysal, T., Güray, E. and Yüksel, Y. (2013) Light-emitting diode photobiomodulation: effect on bone formation in orthopedically expanded suture in rats–early bone changes. *Lasers in Medical Science*, 28, 1263–1270.
7. Kara, M.I., Altan, A.B., Sezer, U., Erdoğan, M.Ş., Inan, S., Ozkut, M. and Nalcacı, R. (2012) Effects of *Ginkgo biloba* on experimental rapid maxillary expansion model: a histomorphometric study. *Oral Surgery, Oral Medicine, Oral Pathology and Oral Radiology*, 114, 712–718.
8. Kara, M.I., Erciyas, K., Altan, A.B., Ozkut, M., Ay, S. and Inan, S. (2012) Thymoquinone accelerates new bone formation in the rapid maxillary expansion procedure. *Archives of Oral Biology*, 57, 357–363.
9. Oztürk, F., Babacan, H., Inan, S. and Gümüş, C. (2011) Effects of bisphosphonates on sutural bone formation and relapse: a histologic and immunohistochemical study. *American Journal of Orthodontics and Dentofacial Orthopedics*, 140, e31–e41.
10. Oztürk, F., Babacan, H. and Gümüs, C. (2012) Effects of zoledronic acid on sutural bone formation: a computed tomography study. *European Journal of Orthodontics*, 34, 141–146.
11. Uysal, T., Amasyali, M., Enhos, S., Sonmez, M.F. and Sagdic, D. (2009) Effect of ED-71, a new active vitamin D analog, on bone formation in an orthopedically expanded suture in rats. A histomorphometric study. *European Journal of Dentistry*, 3, 165–172.
12. Uysal, T., Ustdal, A., Sonmez, M.F. and Ozturk, F. (2009) Stimulation of bone formation by dietary boron in an orthopedically expanded suture in rabbits. *The Angle Orthodontist*, 79, 984–990.
13. Uysal, T., Olmez, H., Amasyali, M., Karslioglu, Y., Yoldas, A. and Gunhan, O. (2010) Response of the expanded inter-premaxillary suture to intermittent compression. Early bone changes. *Australian Orthodontic Journal*, 26, 49–55.
14. Uysal, T., Amasyali, M., Olmez, H., Enhos, S., Karslioglu, Y. and Gunhan, O. (2011) Effect of vitamin C on bone formation in the expanded inter-premaxillary suture. Early bone changes. *Journal of Orofacial Orthopedics*, 72, 290–300.
15. Uysal, T., Gorgulu, S., Yagci, A., Karslioglu, Y., Gunhan, O. and Sagdic, D. (2011) Effect of resveratrol on bone formation in the expanded inter-premaxillary suture: early bone changes. *Orthodontics and Craniofacial Research*, 14, 80–87.
16. Barnes, J., Anderson, L.A. and Phillipson, J.D. (2001) St John's wort (*Hypericum perforatum* L.): a review of its chemistry, pharmacology and clinical properties. *The Journal of Pharmacy and Pharmacology*, 53, 583–600.
17. Newall, C.A., Anderson, L.A. and Phillipson, J.D. (1996) *Herbal Medicines. A Guide for Health-care Professionals*. Pharmaceutical Press, London, UK, 1st edn.
18. Council of Europe. (2000) *Natural Sources of Flavourings. Report No. 1*. Council of Europe Publishing, Strasbourg, France.
19. Franchi, G.G., Nencini, C., Collavoli, E. and Massarelli, P. (2011) Composition and antioxidant activity in vitro of different St. John's Wort (*Hypericum perforatum* L.) extracts. *Journal of Medicinal Plants Research*, 5, 4349–4353.

Downloaded from https://academic.oup.com/ejo/article/37/2/164/2570544 by Erciyes University user on 01 February 2022

20. Hunt, E.J., Lester, C.E., Lester, E.A. and Tackett, R.L. (2001) Effect of St. John's wort on free radical production. *Life Sciences*, 69, 181–190.
21. Davis, P.H. (1967) *Flora of Turkey and the East Aegean Islands*. Edinburgh University Press, Edinburgh, Scotland, Vol. 2.
22. Goldman, S.J. (2004) Practical approaches to psychiatric issues in the orthodontic patient. *Seminars in Orthodontics*, 10, 259–265.
23. Krishnan, V. and Davidovitch, Z. (2006) The effect of drugs on orthodontic tooth movement. *Orthodontics & Craniofacial Research*, 9, 163–171.
24. Cassidy, L.J. and Jellinek, M.S. (1998) Approaches to recognition and management of childhood psychiatric disorders in pediatric primary care. *Pediatric Clinics of North America*, 45, 1037–1052.
25. Linde, K., Ramirez, G., Mulrow, C.D., Pauls, A., Weidenhammer, W. and Melchart, D. (1996) St John's wort for depression–an overview and meta-analysis of randomised clinical trials. *British Medical Journal*, 313, 253–258.
26. Williams, J.W., Jr, Mulrow, C.D., Chiquette, E., Noël, P.H., Aguilar, C. and Cornell, J. (2000) A systematic review of newer pharmacotherapies for depression in adults: evidence report summary. *Annals of Internal Medicine*, 132, 743–756.
27. Knüppel, L. and Linde, K. (2004) Adverse effects of St. John's Wort: a systematic review. *The Journal of Clinical Psychiatry*, 65, 1470–1479.
28. Saito, S. and Shimizu, N. (1997) Stimulatory effects of low-power laser irradiation on bone regeneration in midpalatal suture during expansion in the rat. *American Journal of Orthodontics and Dentofacial Orthopaedics*, 111, e525–e532.
29. Storey, E. (1973) Tissue response to the movement of bones. *American Journal of Orthodontics*, 64, 229–247.
30. Ernst, E. (1999) Second thoughts about safety of St John's wort. *Lancet*, 354, 2014–2016.
31. Hammerness, P., *et al*. (2003) St John's wort: a systematic review of adverse effects and drug interactions for the consultation psychiatrist. *Psychosomatics*, 44, 271–282.
32. Demiroglu, Y.Z., Yeter, T.T., Boga, C., Ozdogu, H., Kizilkilic, E., Bal, N., Tuncer, İ. and Arslan, H. (2005) Bone marrow necrosis: a rare complication of herbal treatment with *Hypericum perforatum* (St. John's wort). *Acta Medica*, 48, 91–94.
33. Bray, B.J., Perry, N.B., Menkes, D.B. and Rosengren, R.J. (2002) St. John's wort extract induces CYP3A and CYP2E1 in the Swiss Webster mouse. *Toxicological Sciences*, 66, 27–33.
34. Elghazaly, M.A., Elsabbagh, W.A., Zaki, H.F., Ramadan, L.A. and Kenawy, S.A. (2011) Effect of long-term treatment with fluoxetine, clomipramine and St. John' s wort extract on bone turnover in female irradiated rats. *Egyptian Journal of Basic and Clinical Pharmacology*, 1, 43–50.
35. Leuner, K., Kazanski, V., Müller, M., Essin, K., Henke, B., Gollasch, M., Harteneck, C. and Müller, W.E. (2007) Hyperforin–a key constituent of St. John's wort specifically activates TRPC6 channels. *FASEB Journal*, 21, 4101–4111.
36. Bab, I. and Yirmiya, R. (2010) Depression, selective serotonin reuptake inhibitors, and osteoporosis. *Current Osteoporosis Reports*, 8, 185–191.
37. Kumar, A., Garg, R. and Prakash, A.K. (2010) Effect of St. John's Wort (*Hypericum perforatum*) treatment on restraint stress-induced behavioral and biochemical alteration in mice. *BMC Complementary and Alternative Medicine*, 10, 18.
38. Paterniti, I., Briguglio, E., Mazzon, E., Galuppo, M., Oteri, G., Cordasco, G. and Cuzzocrea, S. (2010) Effects of *Hypericum perforatum*, in a rodent model of periodontitis. *BMC Complementary and Alternative Medicine*, 10, 73.
39. Crockett, S.L., Poller, B., Tabanca, N., Pferschy-Wenzig, E., Wedge, D.E. and Bucar, F.J. (2011) Bioactive xanthones from the roots of *Hypericum perforatum* (common St John's wort). *Journal of the Science of Food and Agriculture*, 91, 428–434.
40. Sánchez-Reus, M.I., Gómez del Rio, M.A., Iglesias, I., Elorza, M., Slowing, K. and Benedí, J. (2007) Standardized *Hypericum perforatum* reduces oxidative stress and increases gene expression of antioxidant enzymes on rotenone-exposed rats. *Neuropharmacology*, 52, 606–616.

Downloaded from https://academic.oup.com/ejo/article/37/2/164/2570544 by Erciyes University user on 01 February 2022